**PATIENT**

Arty Parker

SPECIES

Canine

BREED

Coonhound Mix

SEX

FS

AGE

10 years

WEIGHT

70 #

INTERPRETED BYRemo Lobetti, BVSc,
MMedVet (Med), PhD, Dipl.
ECVIM**IMAGING PERFORMED BY**

Sarah Pender, CVT

HOSPITAL NAME

SVS Imaging QC

REFERRING VET

Dr Sue Hartmann

INVOICE

303695

DATE

12/22/22

PRESENTING CLINICAL SIGNS

History: Chronic arthritis on Novox® – blood work for NSAID screen. Occasional GI issues if eats human food.

Physical Examination: Normal.

Urinalysis: N/A.

CBC: N/A.

Serum Biochemistry: Elevated ALP activity and mildly elevated ALT activity.

Radiographic Findings: N/A.

ULTRASONOGRAPHIC EXAMINATION OF THE ABDOMEN**Urinary System**

Full urinary bladder with a normal thickness and appearance of the wall. Normal anechoic urine with no sediment or uroliths evident.

Normal trigone area, proximal urethra, and iliac blood vessels.

Normal iliac lymph nodes. Ureters not evident.

Normal renal size (left 7.2 cm, right 7 cm) with increased echogenic appearance, some loss of cortico-medullary differentiation, and normal pelvis and capsule.

Reproductive System

N/A.

Adrenal Glands

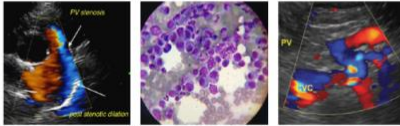
Normal position, shape, and echogenic appearance. Normal size of left (2.56 x 0.58/0.56 cm) and enlarged right gland (3.08 x 0.78 cm).

Spleen

Normal size and echogenic appearance. Smooth homogenous parenchyma, smooth curvi-linear capsule, and normal vasculature. No evidence of inflammatory, neoplastic, infarction, or infiltrative changes noted.

Liver

Normal size with a diffuse mottled echogenic and nodular appearance, some loss of portal markings, and regular curvilinear capsule. Nodules are faint hypoechogenic, parenchymal, and of varying sizes. Full gall bladder containing small amount of hyperechogenic sediment. Normal thickness and echogenic appearance of the gall bladder wall. Normal bile duct.

**PATIENT**

Arty Parker

SPECIES

Canine

BREED

Coonhound Mix

SEX

FS

AGE

10 years

WEIGHT

70 #

INTERPRETED BYRemo Lobetti, BVSc,
MMedVet (Med), PhD, Dipl.
ECVIM**IMAGING PERFORMED BY**

Sarah Pender, CVT

HOSPITAL NAME

SVS Imaging QC

REFERRING VET

Dr Sue Hartmann

INVOICE

303695

DATE

12/22/22

Gastrointestinal

Normal appearance of the stomach, duodenum, small intestine, ileo-cecal junction, and colon with no loss of layering, normal wall thickness and peristaltic activity, and no distension of the lumen.

Pancreas

Normal size and echogenic appearance. Regular capsule. Normal echogenic appearance of the mesentery and fat surrounding the pancreas.

Free Abdomen

No mesenteric lymphadenomegaly.
No ascites.

ULTRASONOGRAPHIC FINDINGS

Primary Findings:

- Nodular hepatopathy.
- Right adrenomegaly.

Secondary Findings:

- Gall bladder sediment.
- Age-related renal changes.

INTERPRETATION OF THE FINDINGS & FURTHER RECOMMENDATIONS

Etiologies for the hepatopathy would reactive, drug-induced, nodular hyperplasia, granulomatous disease, chronic hepatitis, and neoplasia.

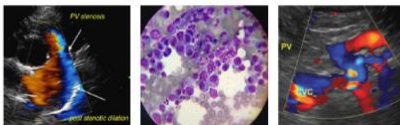
The most likely etiology for the adrenomegaly would be disease stress with emerging Cushing's disease, a differential diagnosis.

Further assessment would be FNA cytology of the liver and possibly adrenal function testing (ACTH stimulation/LDDS test). Tru-Cut/wedge biopsy of the liver may, however, be required for a specific etiological diagnosis.

Specific therapy would be dependent on an etiological diagnosis. Symptomatic management of the liver and gall bladder would be ursodiol. As the liver changes may be secondary to the Novox®, discontinuing it would be indicated but consultation with a pain specialist should be considered for more specific management of the arthritis.

IMAGING PERFORMED BY

svsmobileimaging.com 309-737-3070



Clinical Sonography & Telectology

EDUCATIONAL TELECONSULTATION SERVICES™

1-800-838-4268 info@sonopath.com SonoPath.com

PATIENT

Arty Parker

SPECIES

Canine

BREED

Coonhound Mix

SEX

FS

AGE

10 years

WEIGHT

70 #

INTERPRETED BY

Remo Lobetti, BVSc,
MMedVet (Med), PhD, Dipl.
ECVIM

IMAGING PERFORMED BY

Sarah Pender, CVT

HOSPITAL NAME

SVS Imaging QC

REFERRING VET

Dr Sue Hartmann

INVOICE

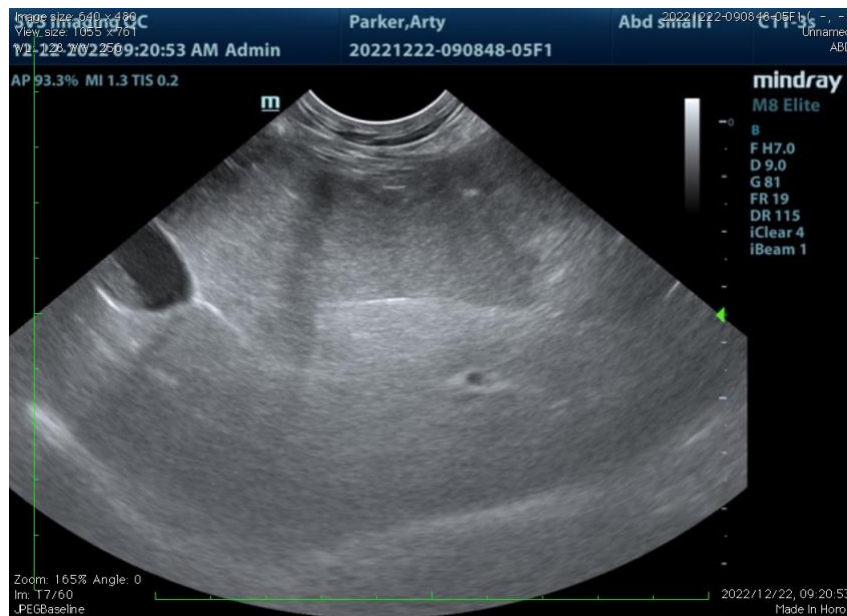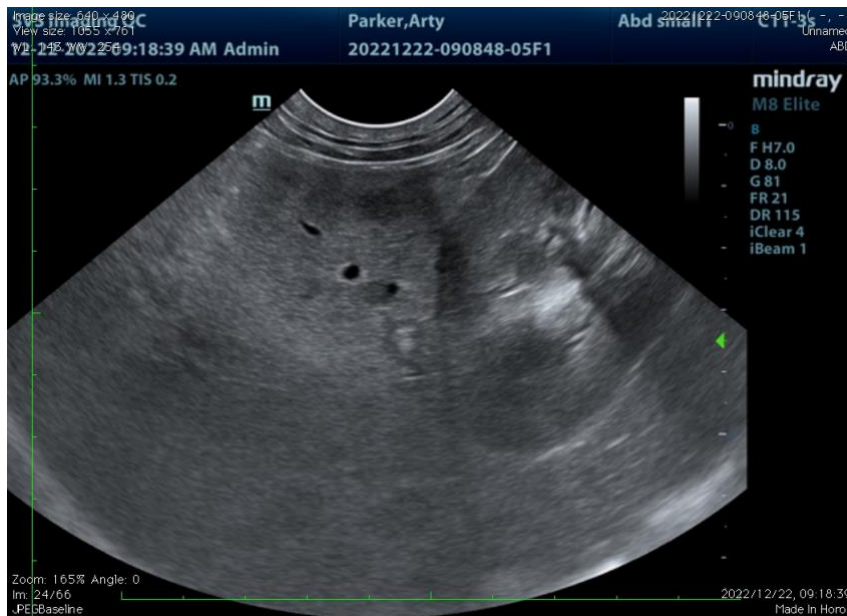303695

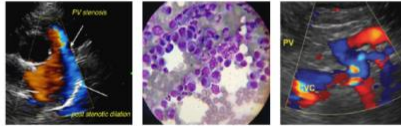
DATE

12/22/22

IMAGES

Liver





PATIENT

Gall bladder

Arty Parker

SPECIES

Canine

BREED

Coonhound Mix

SEX

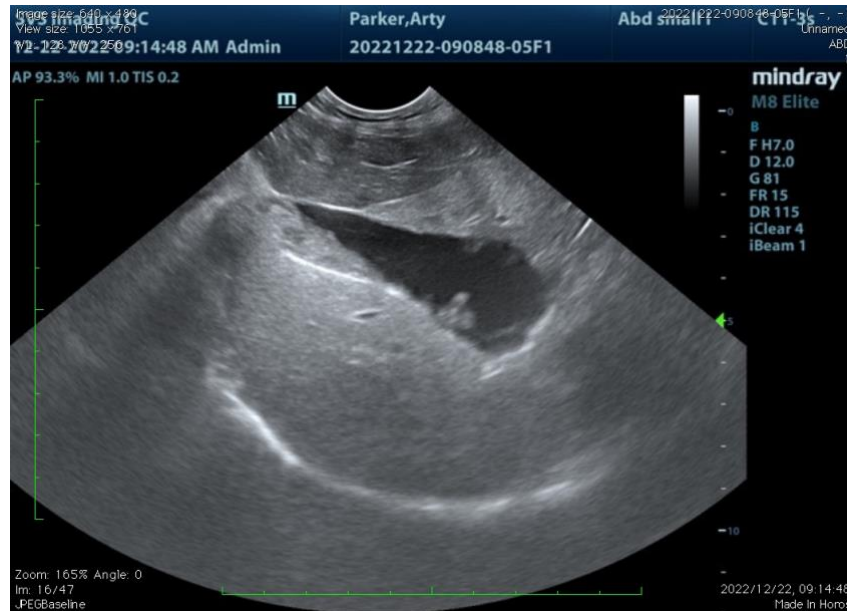FS

AGE

10 years

WEIGHT

70 #



INTERPRETED BY

The information and recommendations provided are based on the images presented by the referring veterinarian. No evaluation can be communicated regarding pathology that was not visible in the image/video clips provided.

Remo Lobetti, BVSc, MMedVet (Med), PhD, Dipl. ECVIM

Thank you for this referral. If the clinical or image interpretation does not parallel your findings or if I can be of any further assistance, please contact me.

IMAGING PERFORMED BY

Remo Lobetti, BVSc, MMedVet (Med), PhD, Dipl. ECVIM (Internal Medicine)
rlobetti@mweb.co.za

Sarah Pender, CVT

HOSPITAL NAME

SVS Imaging QC

REFERRING VET

Dr Sue Hartmann

INVOICE

303695

DATE

12/22/22